



Caso problema:

Luxación protésica inveterada

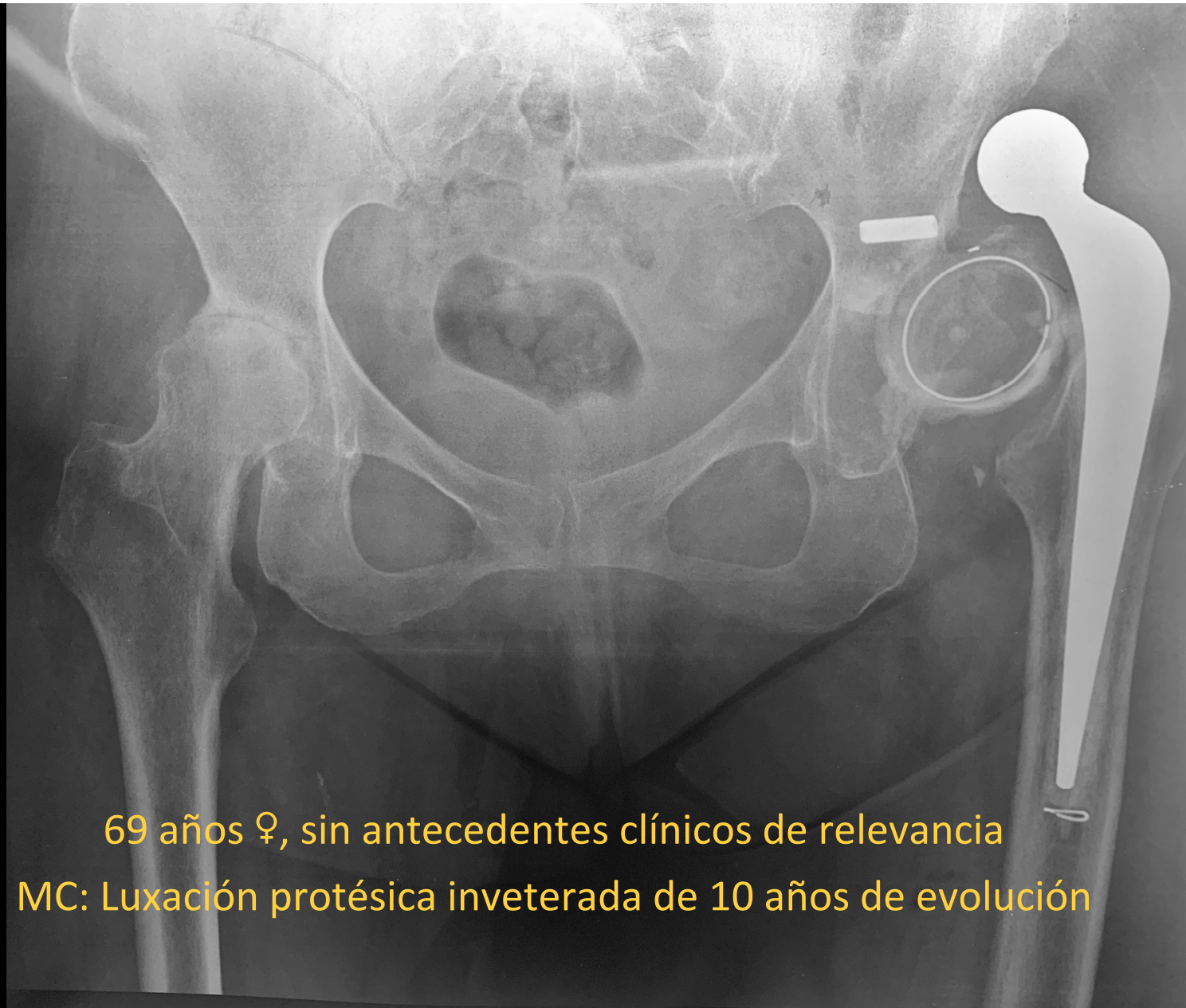Equipo GRECARO

Dr. Tillet Fernando

Dr. Bochaty Eduardo

Dr. Lopreite Fernando



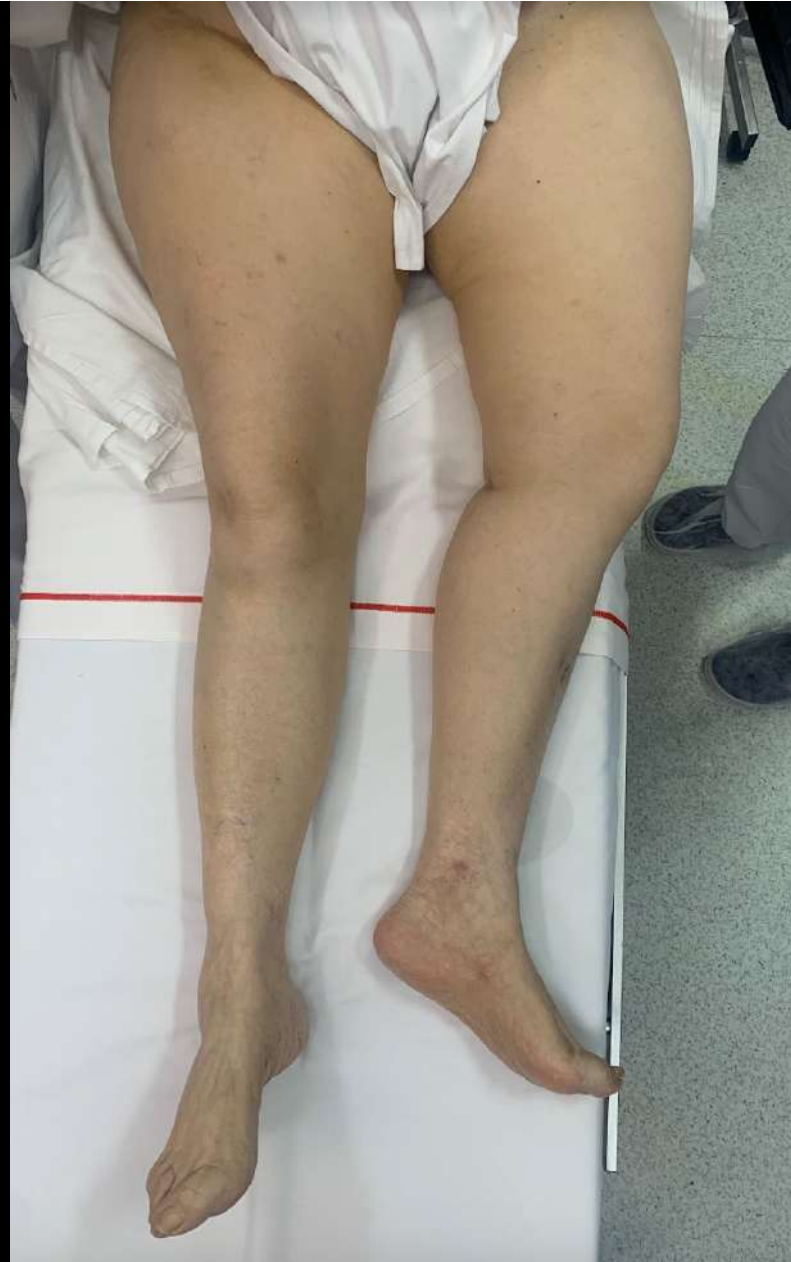

69 años ♀, sin antecedentes clínicos de relevancia

MC: Luxación protésica inveterada de 10 años de evolución

Examen físico:

**Acortamiento e
impotencia funcional de
mmii izquierdo**

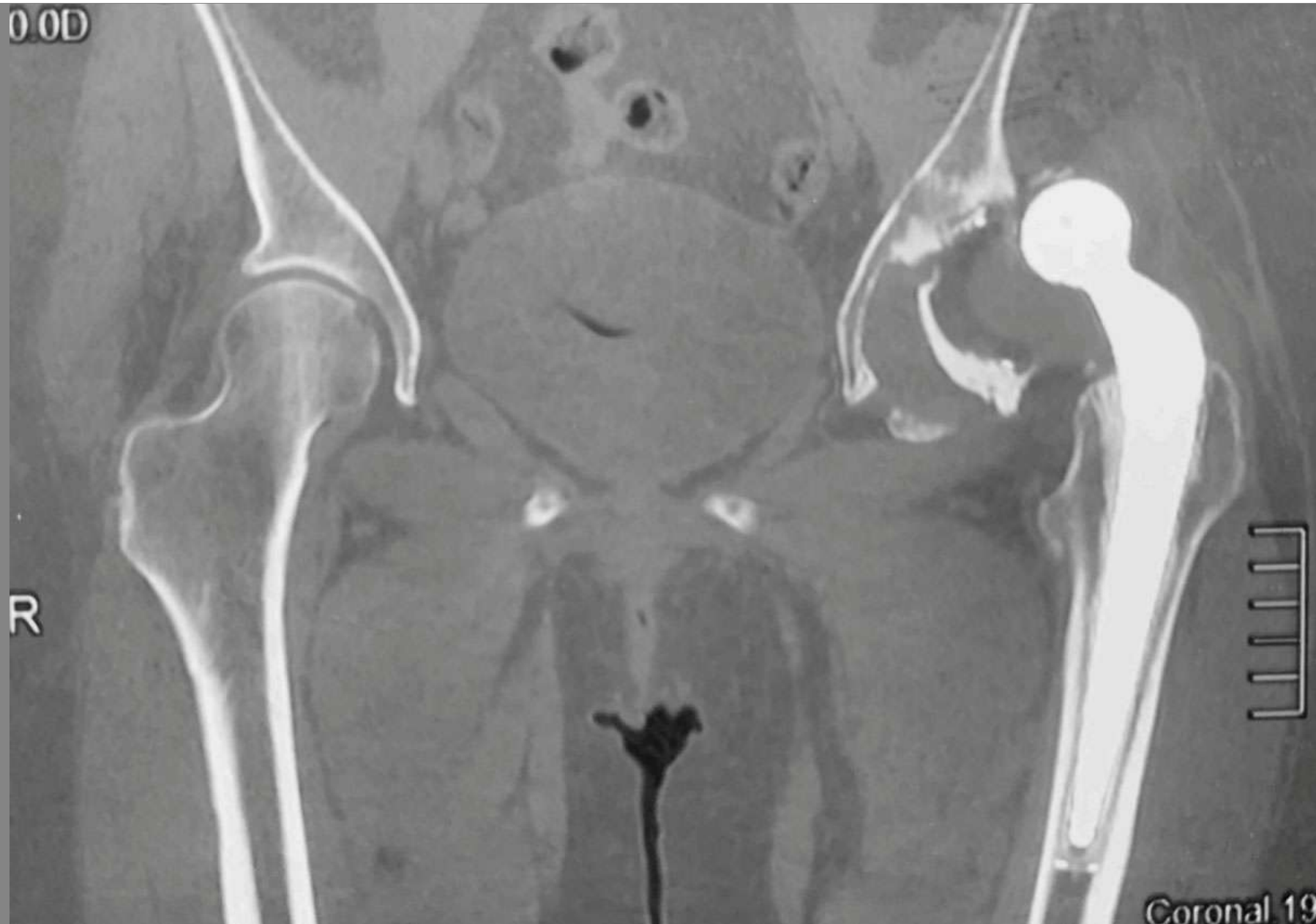

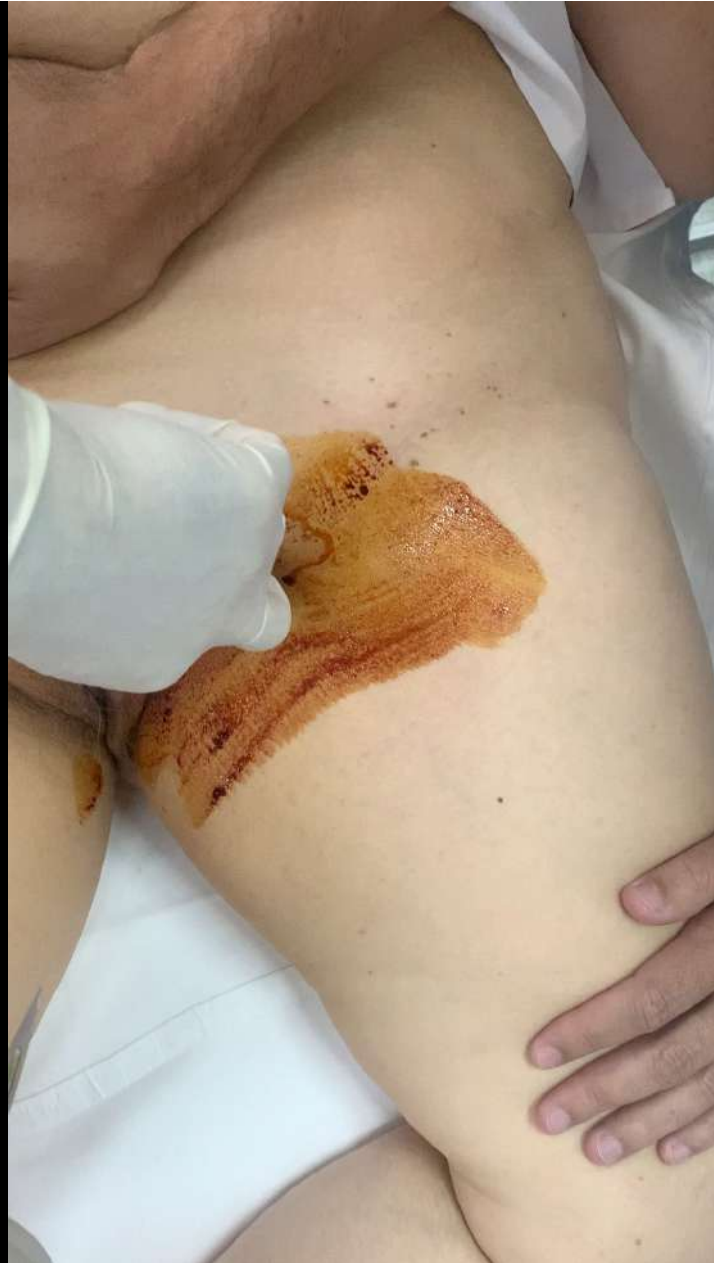0.0D

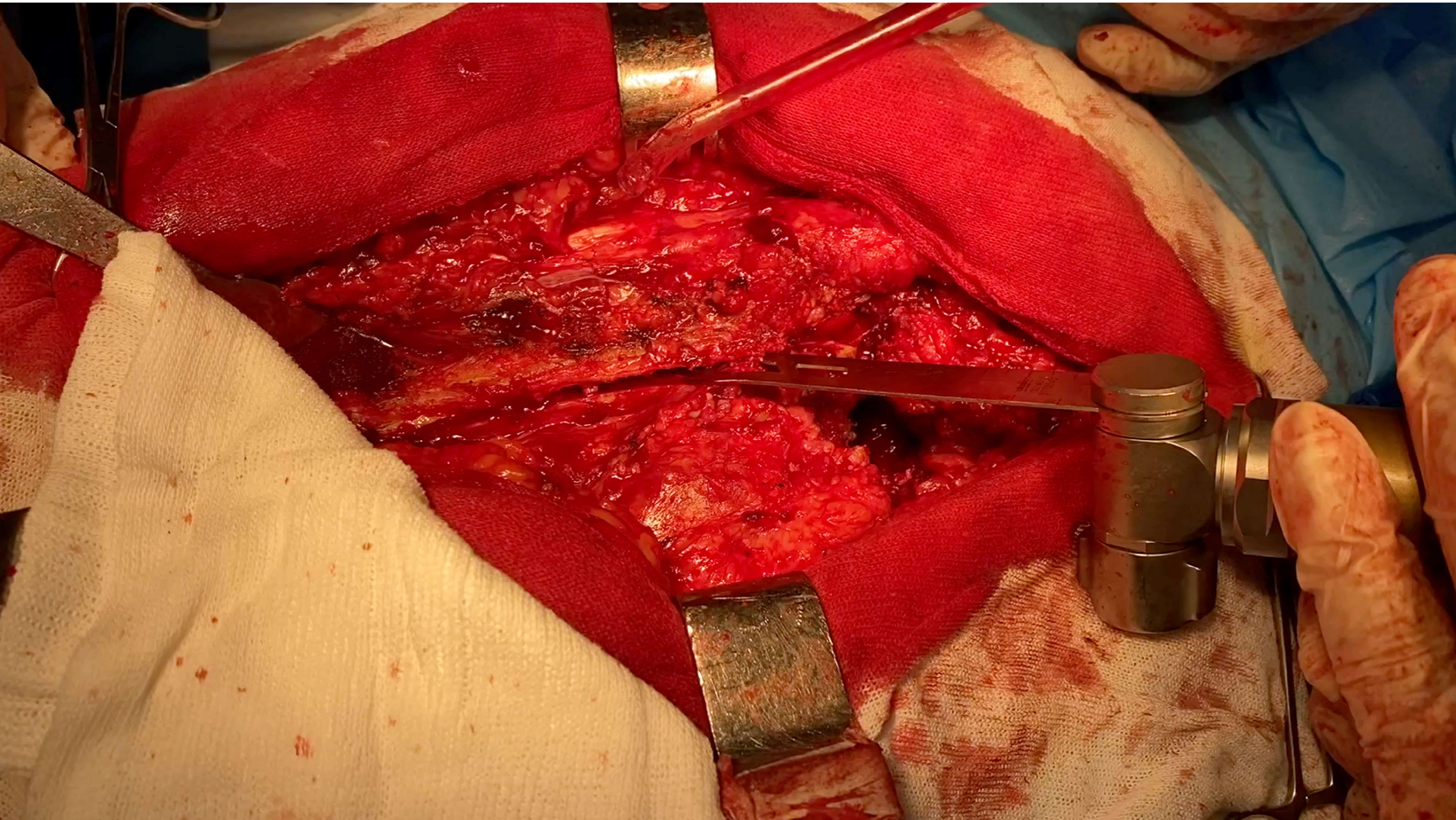
R

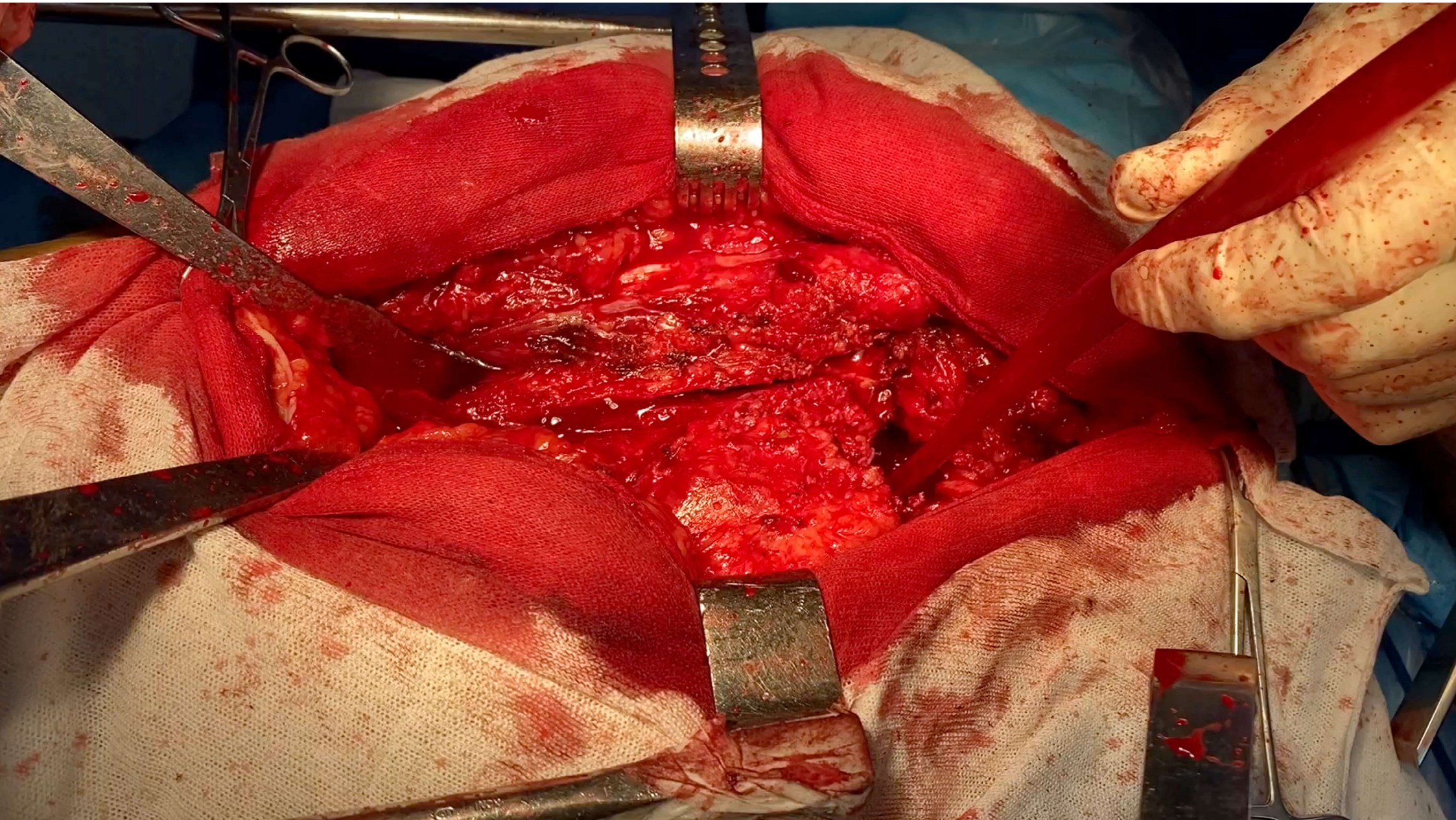


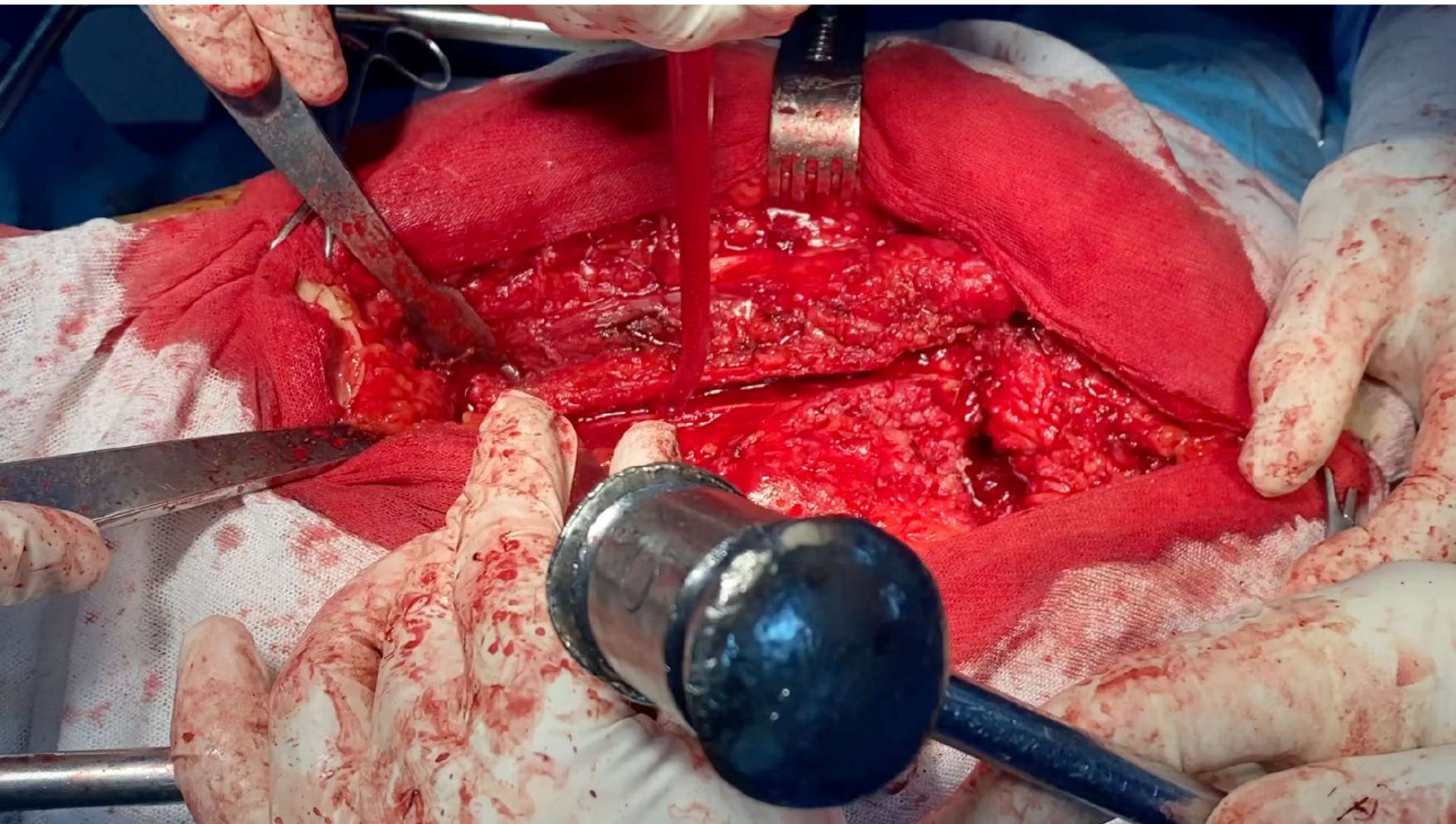
Coronal 19

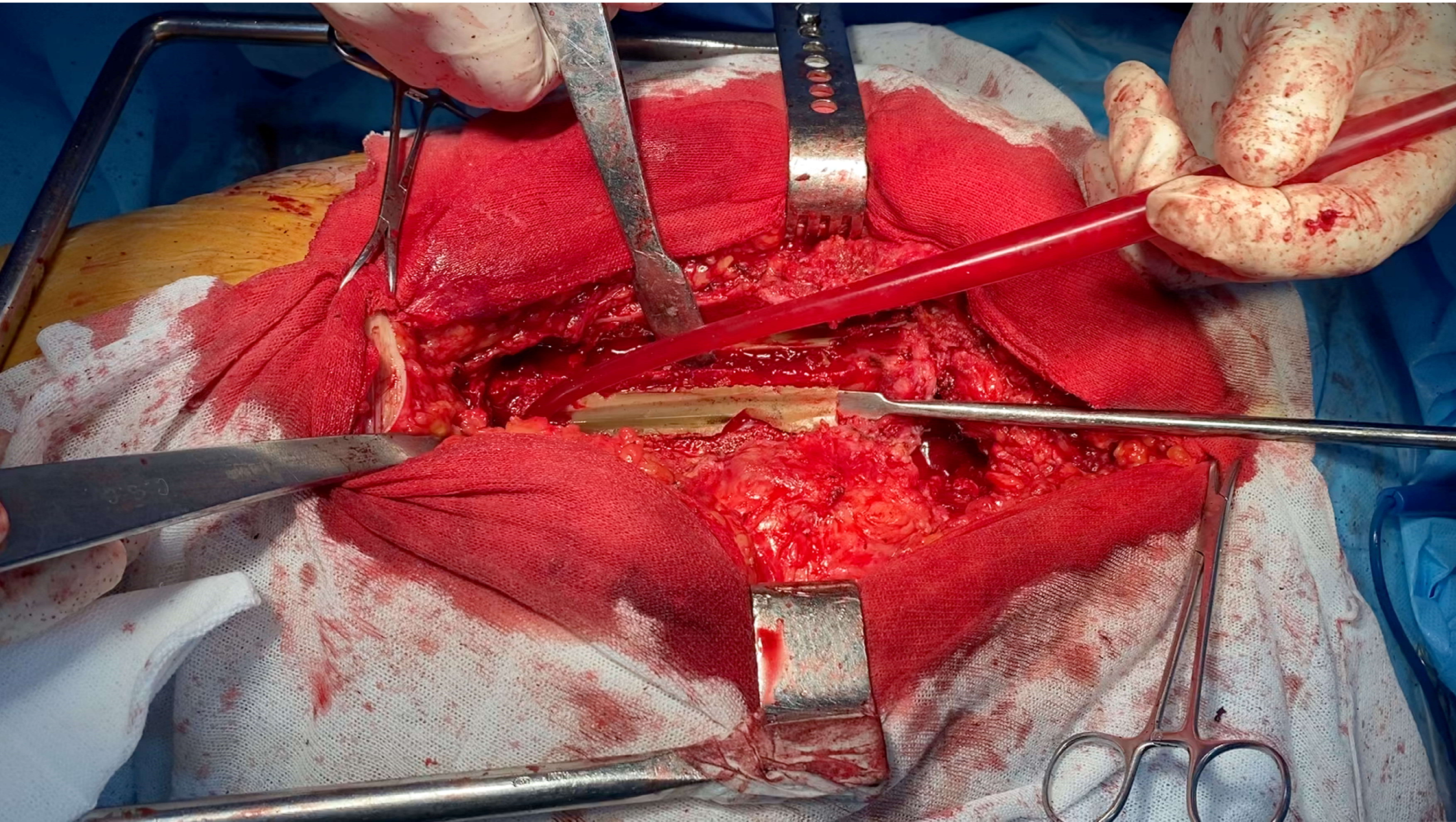


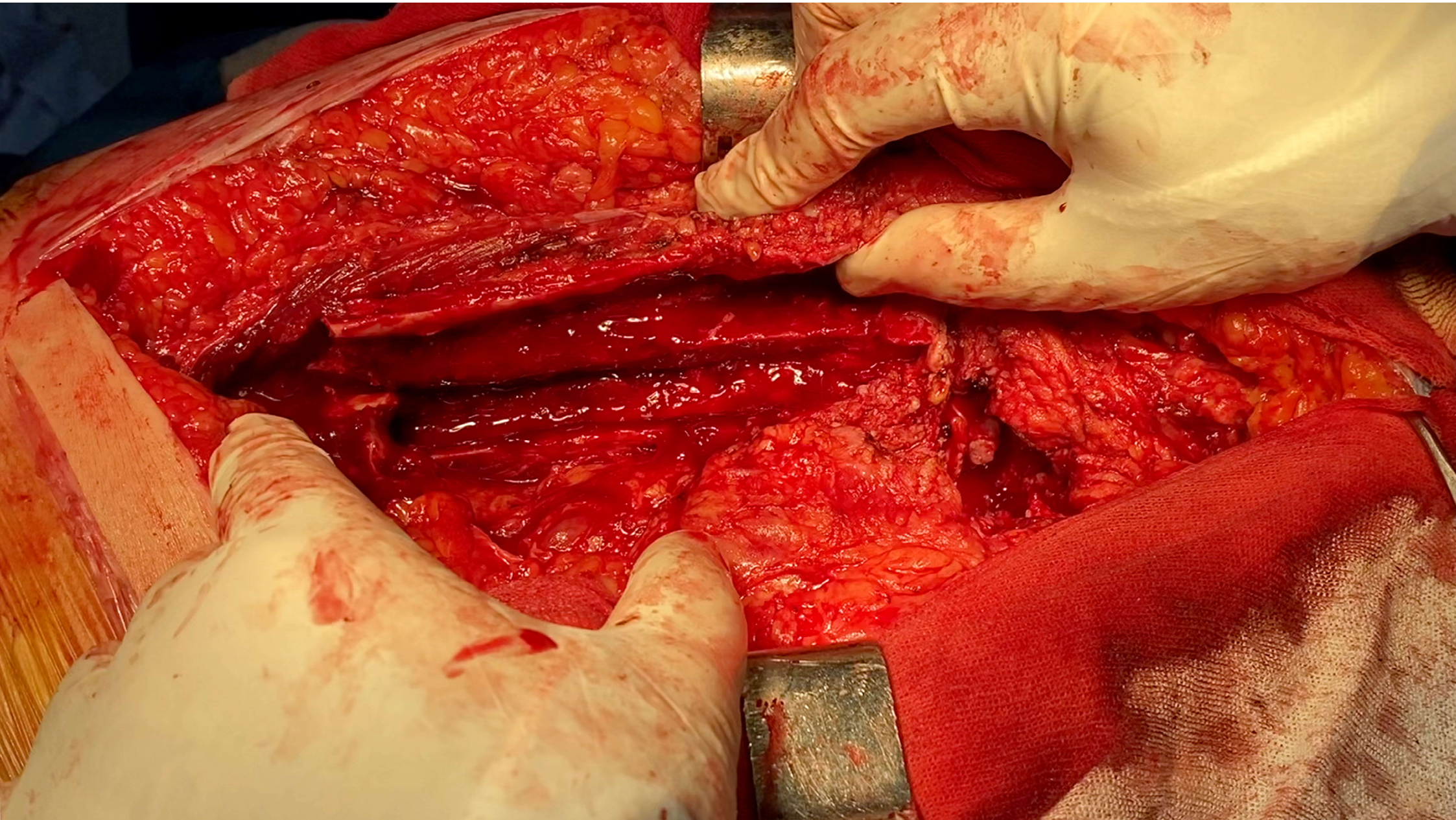


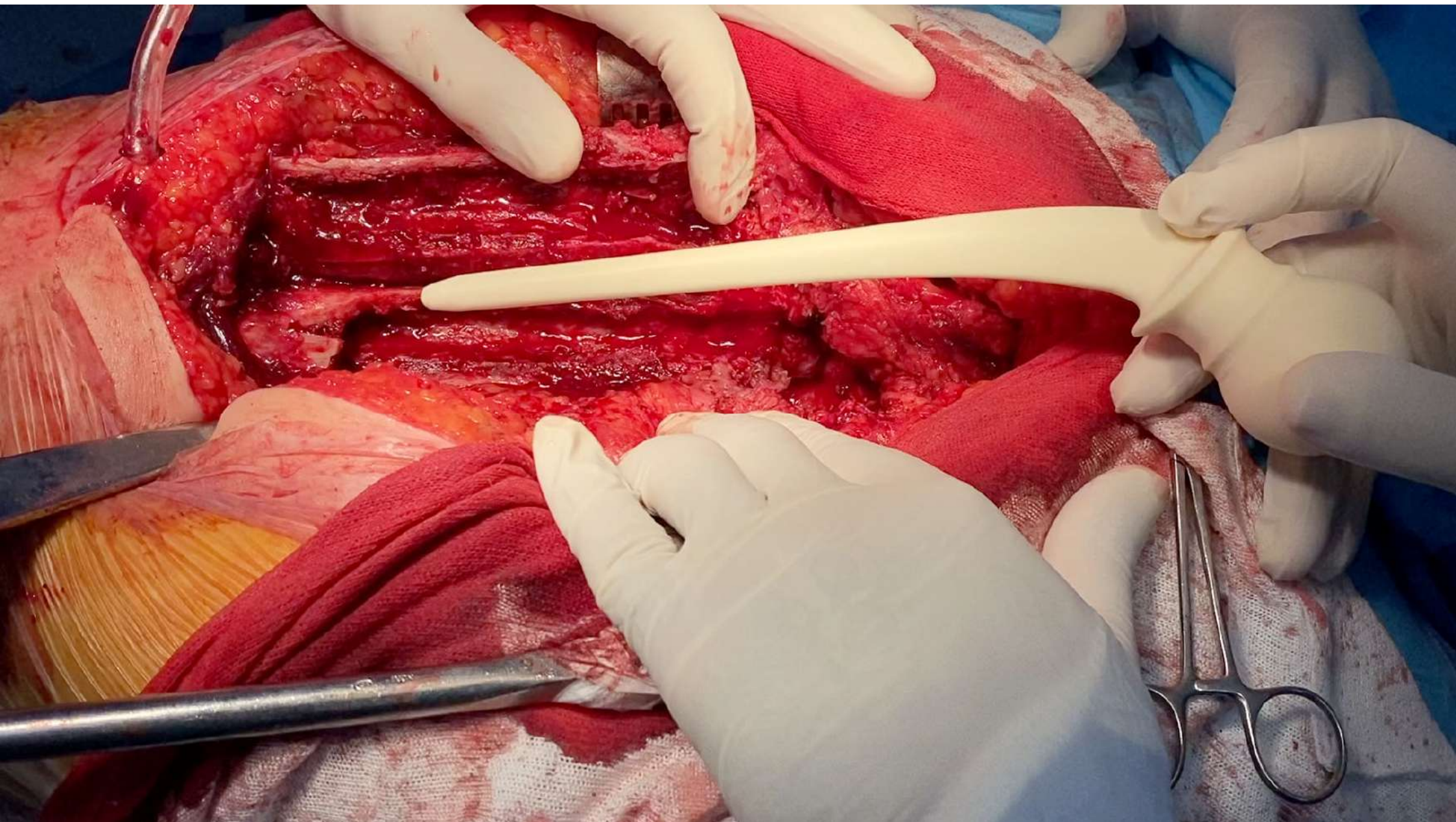

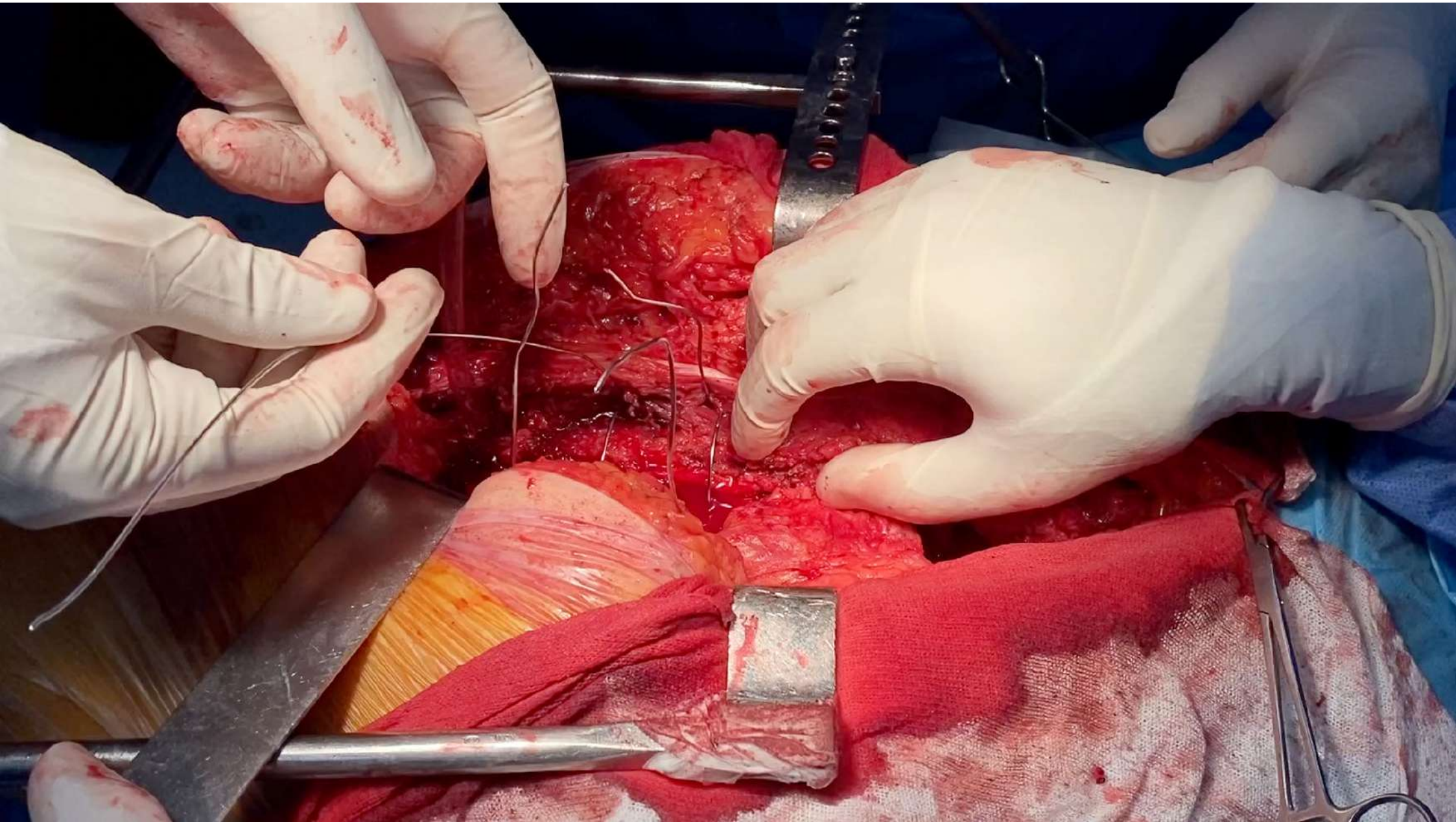



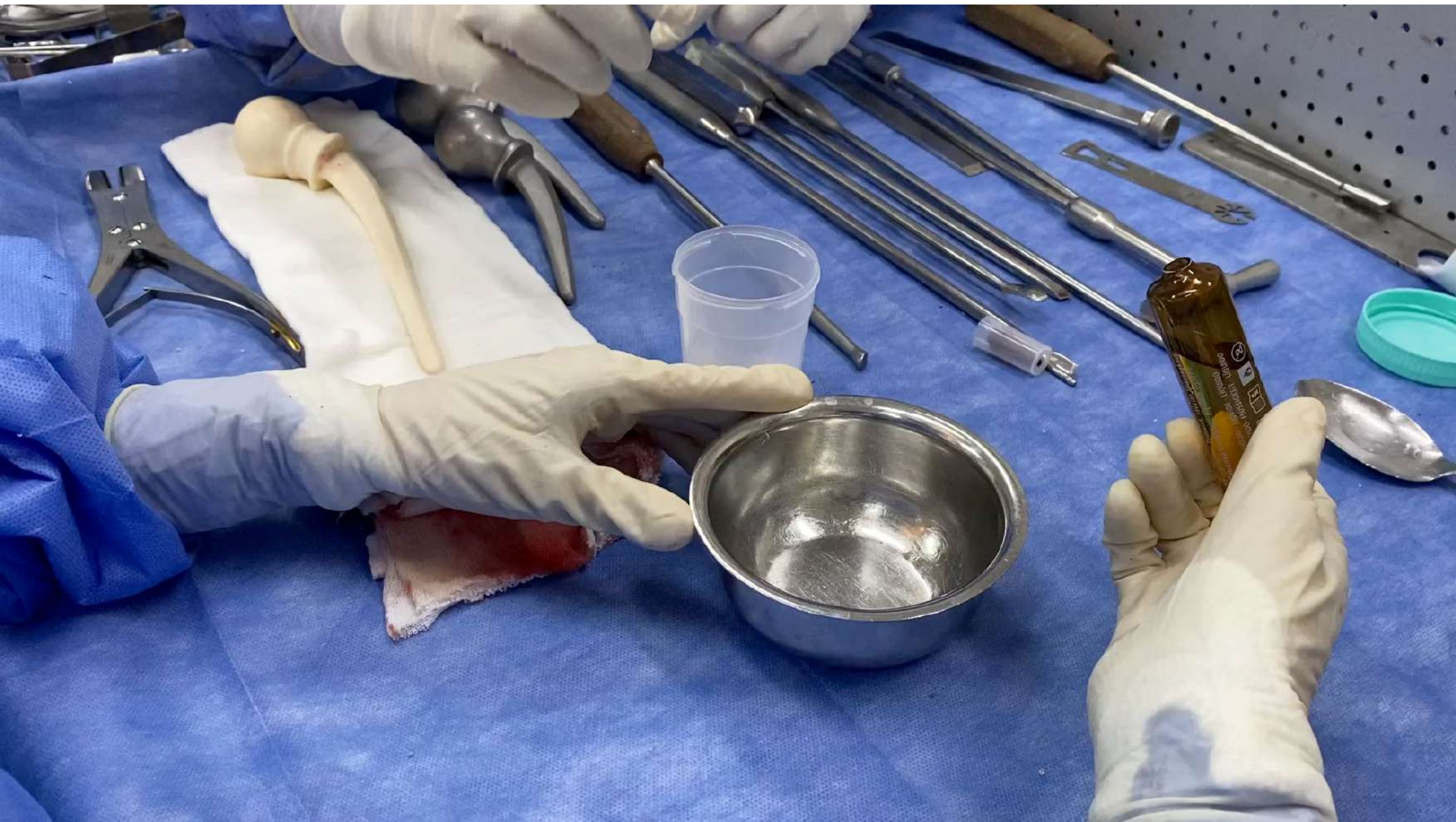


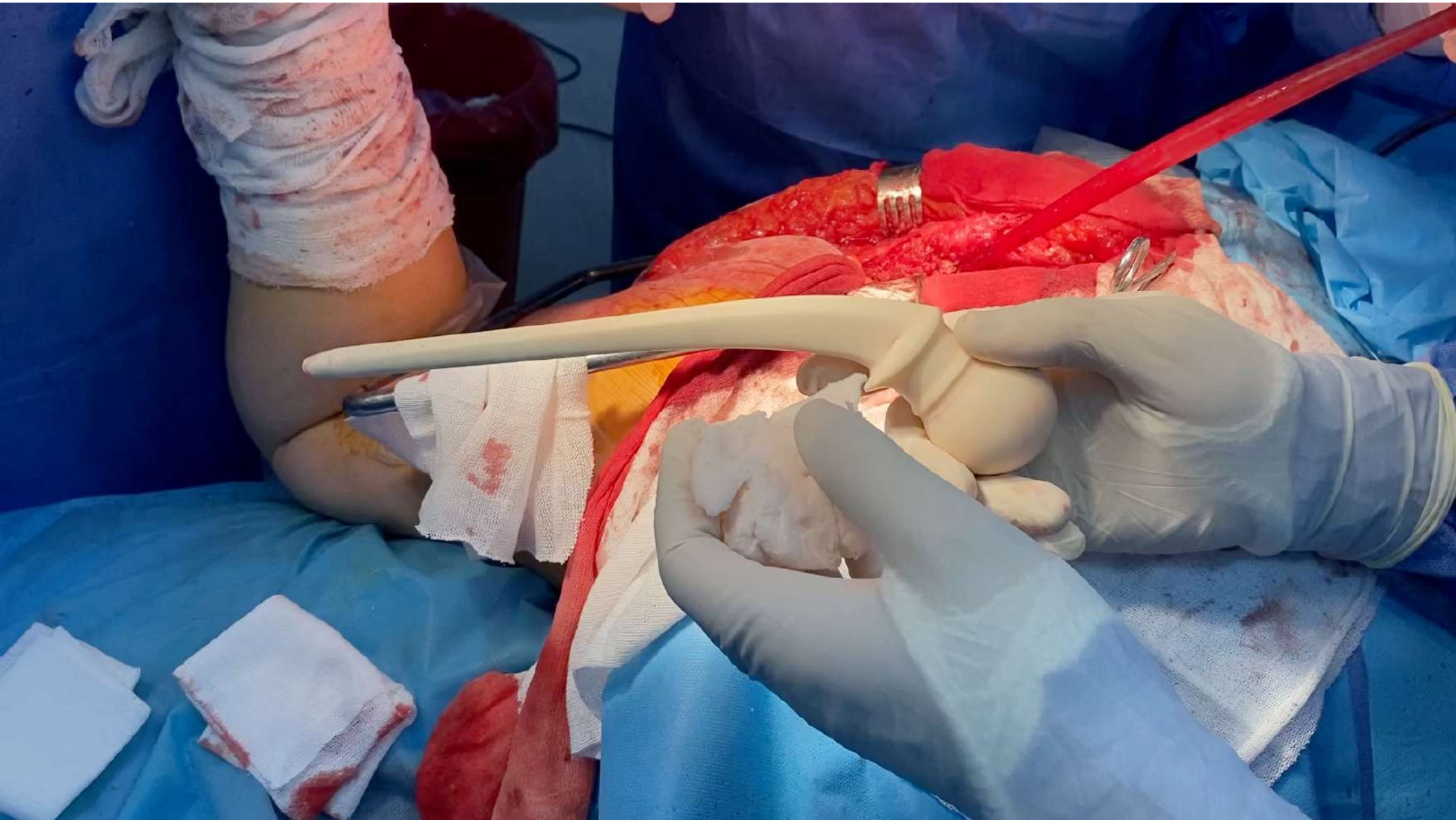


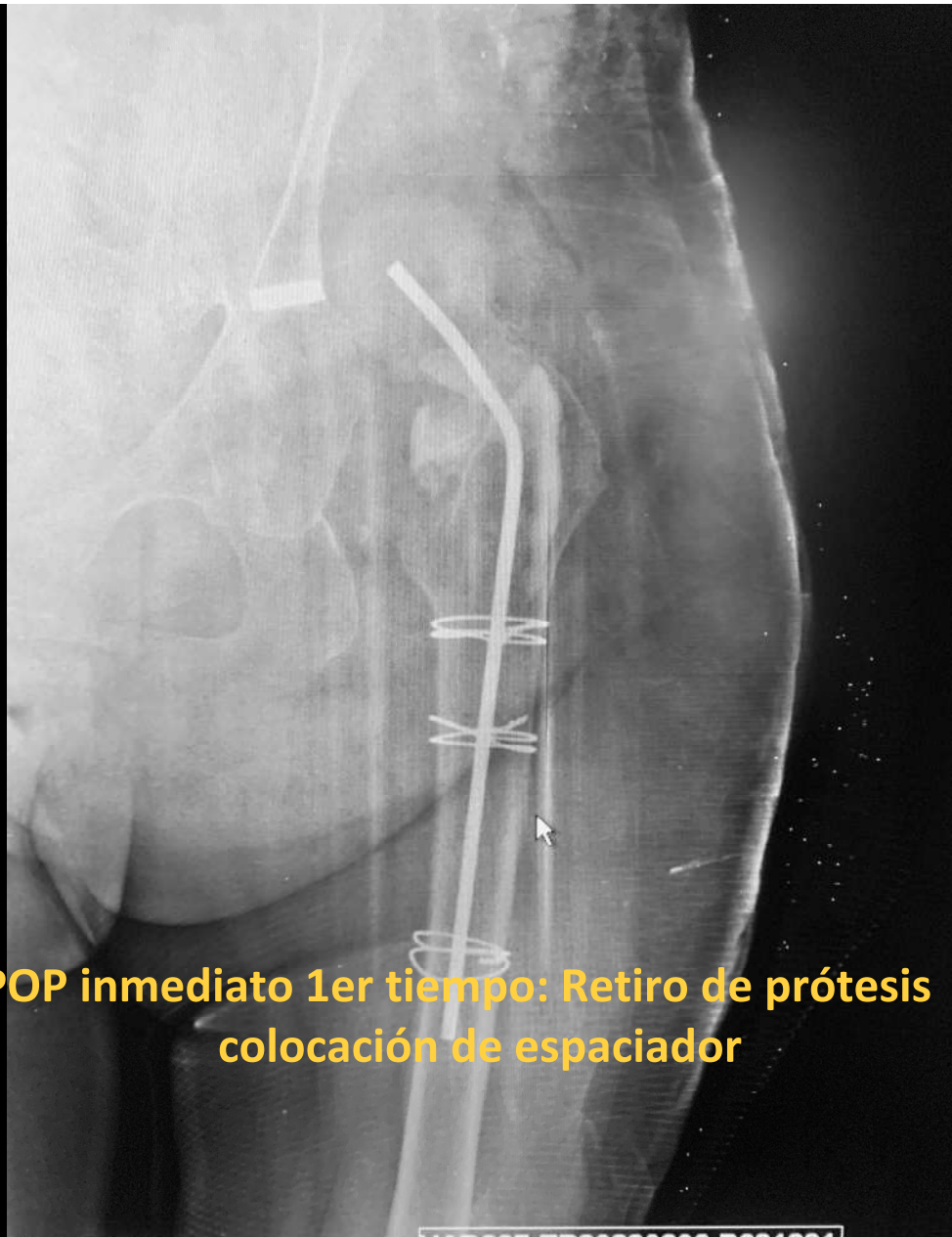
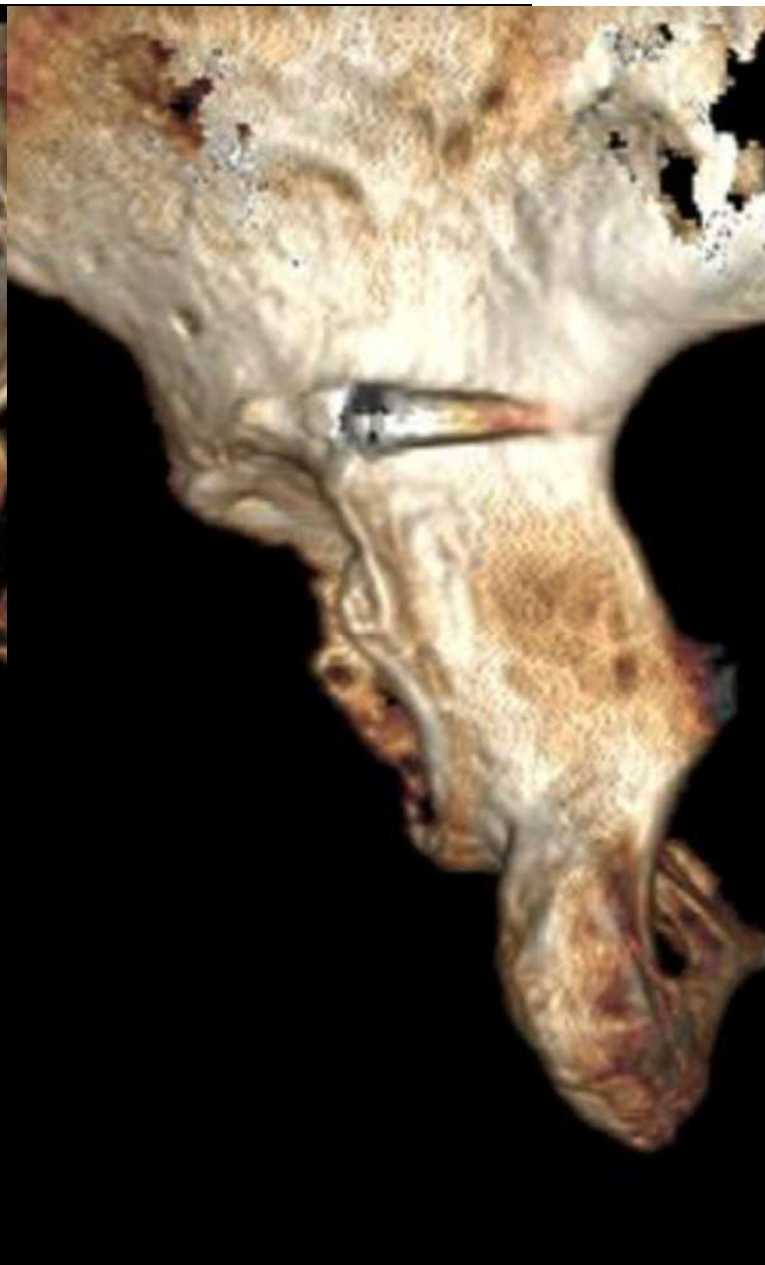




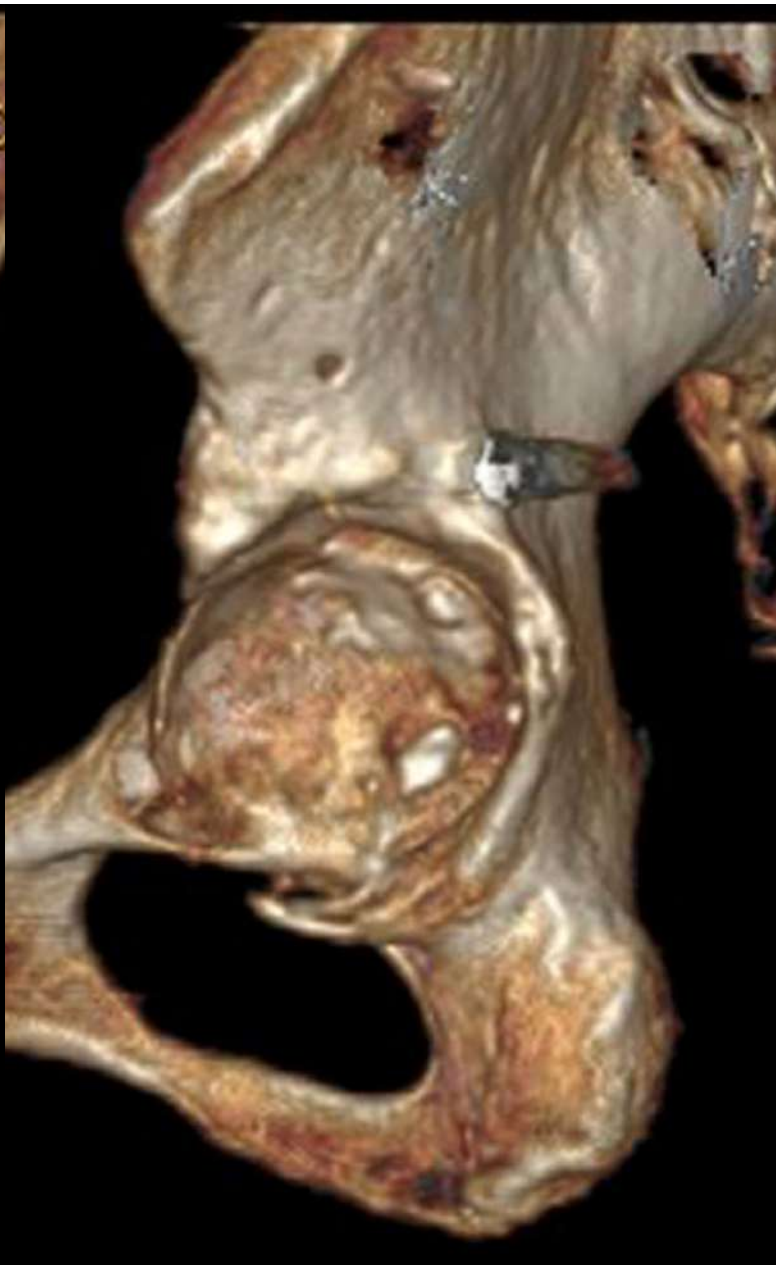
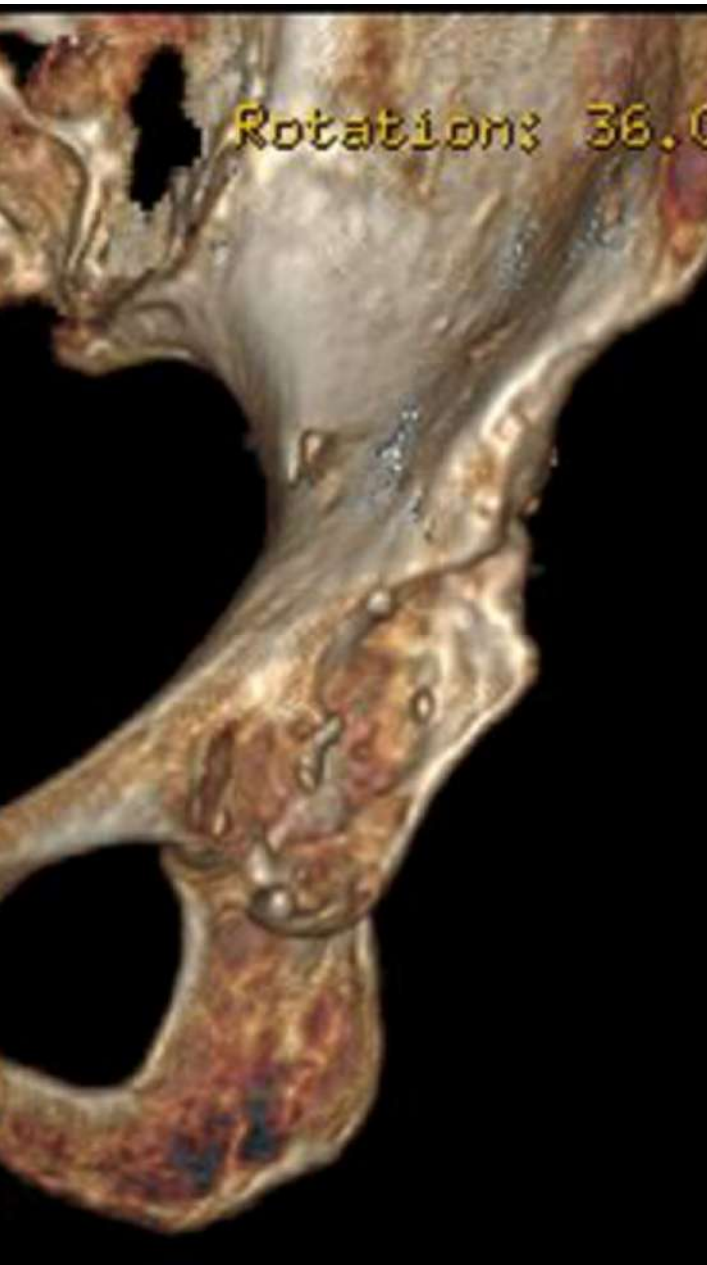


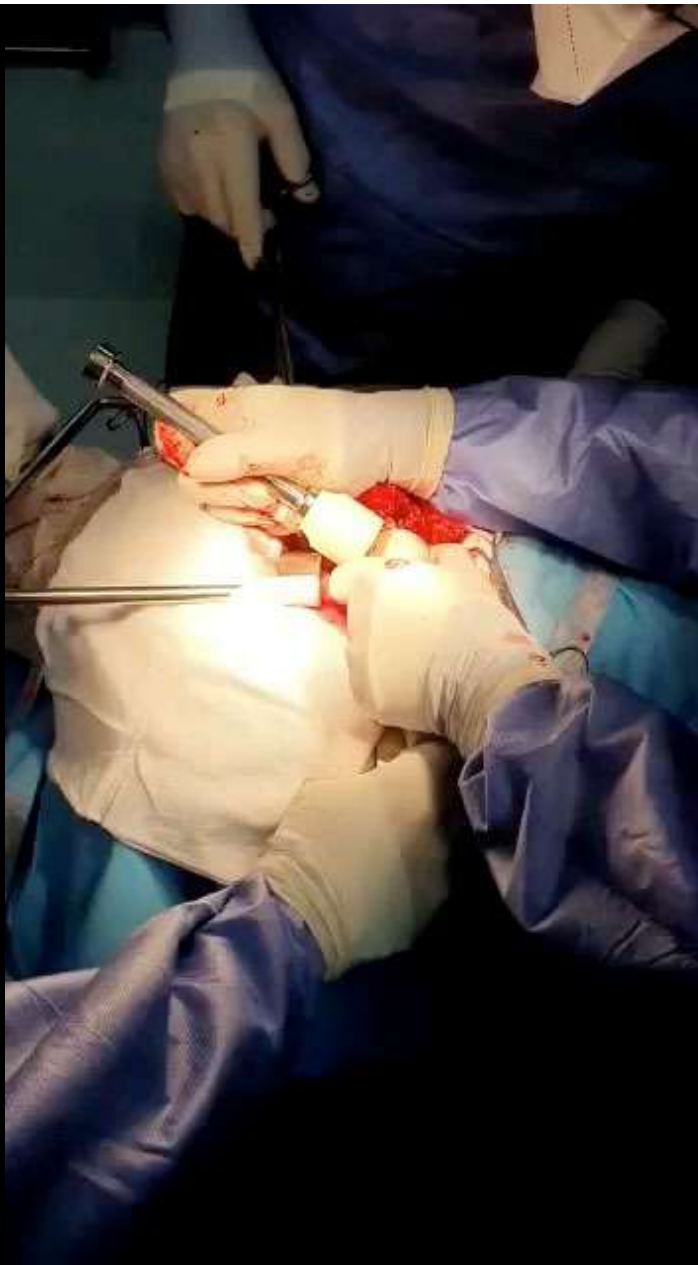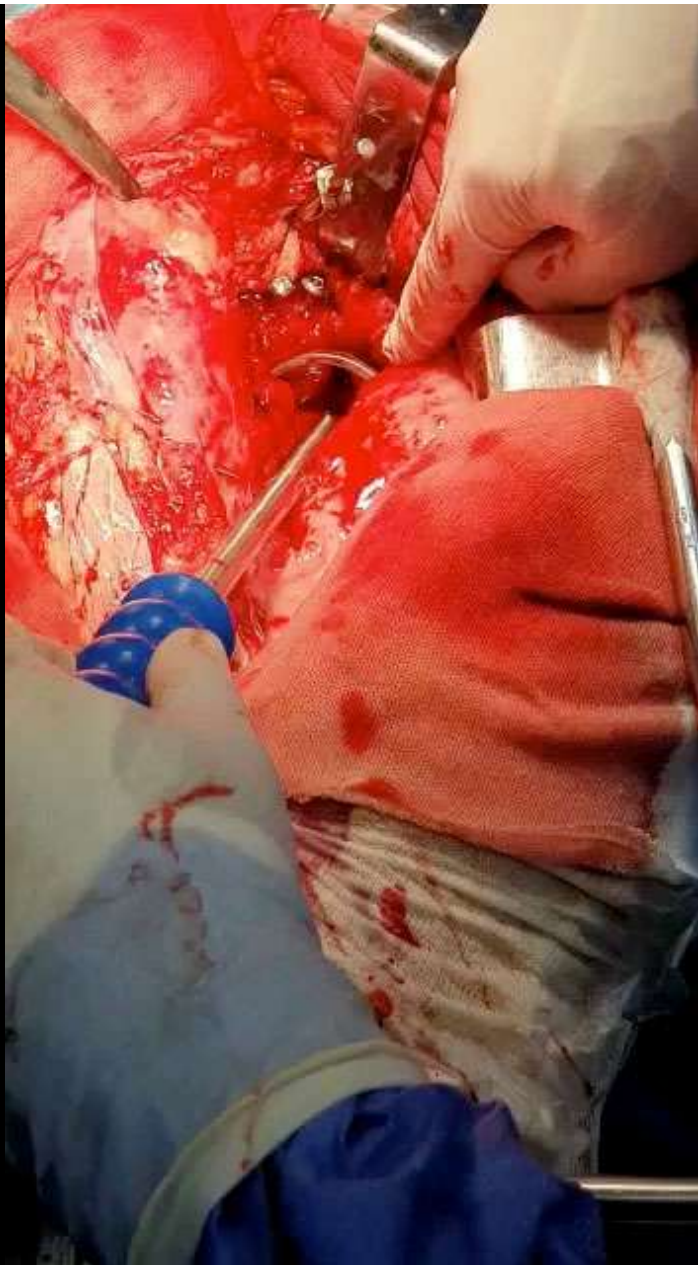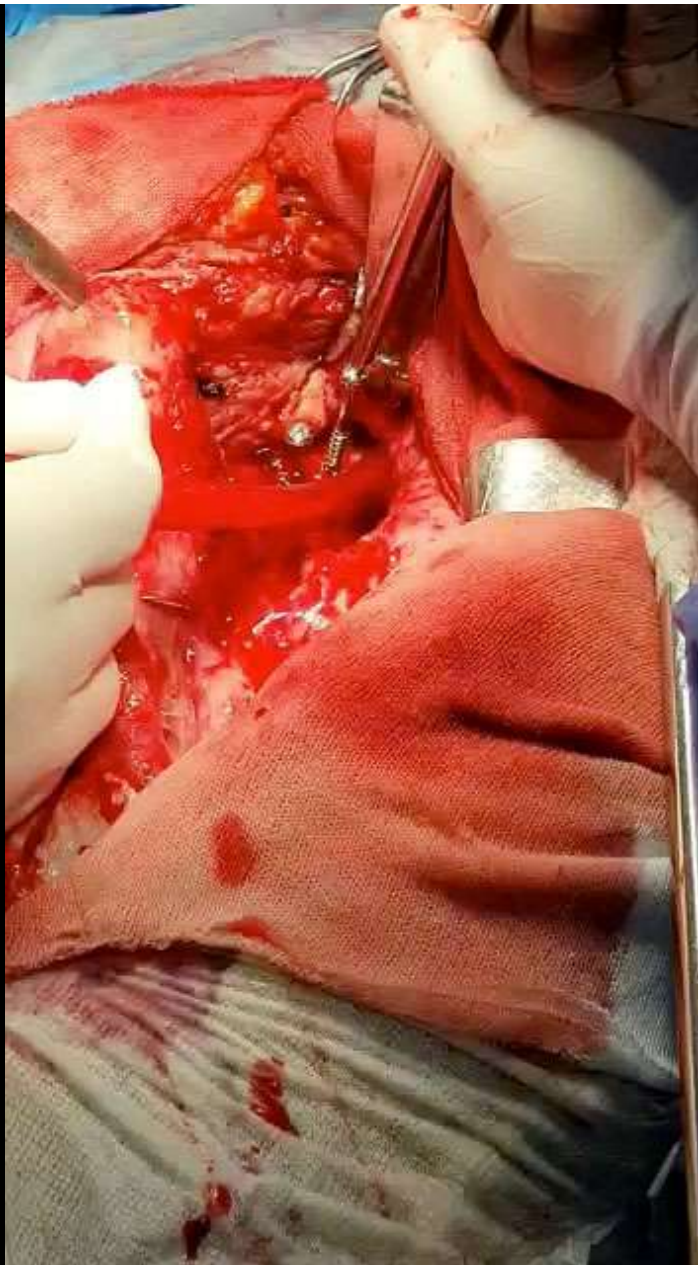**POP inmediato 1er tiempo: Retiro de prótesis +
colocación de espaciador**

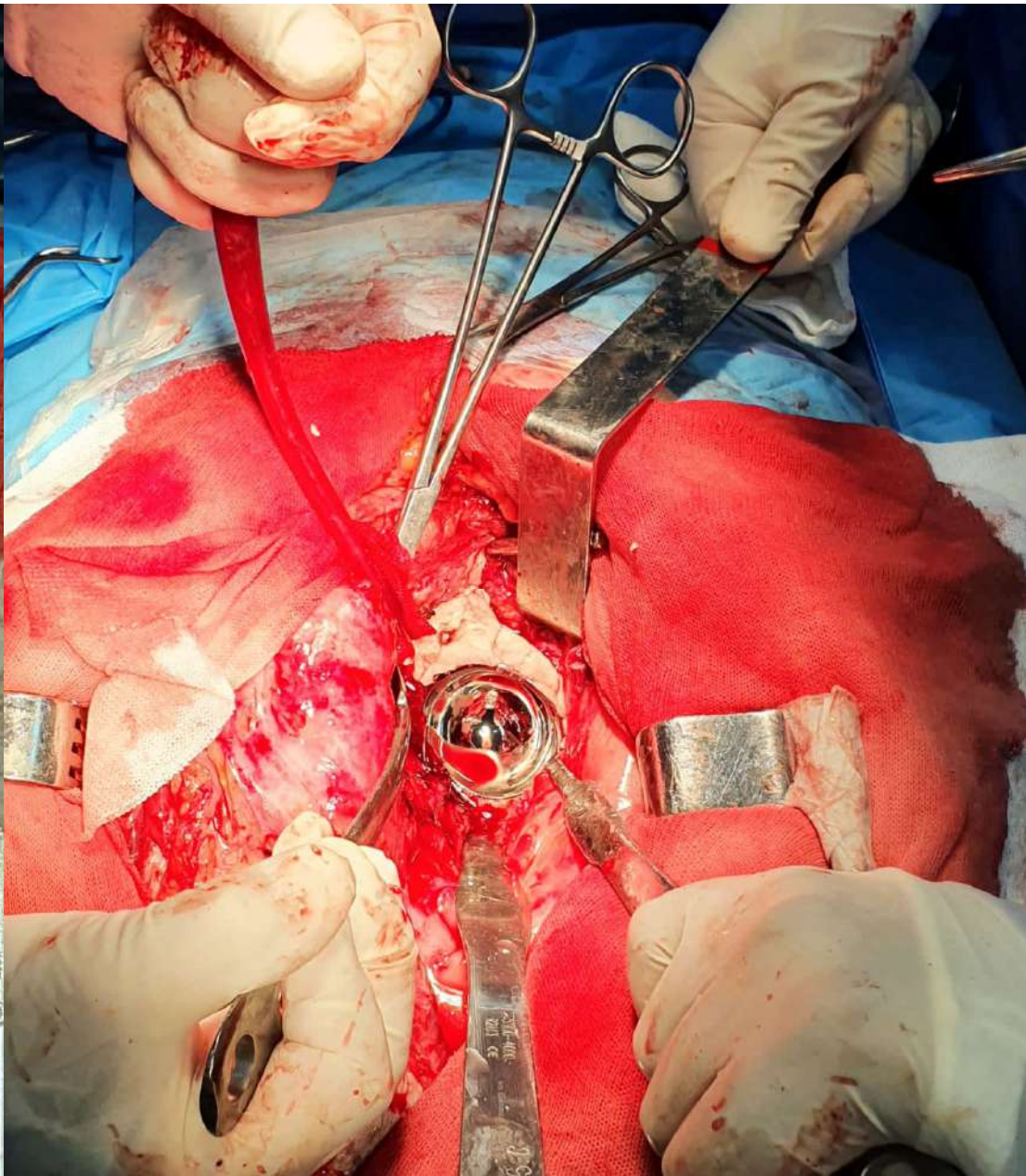
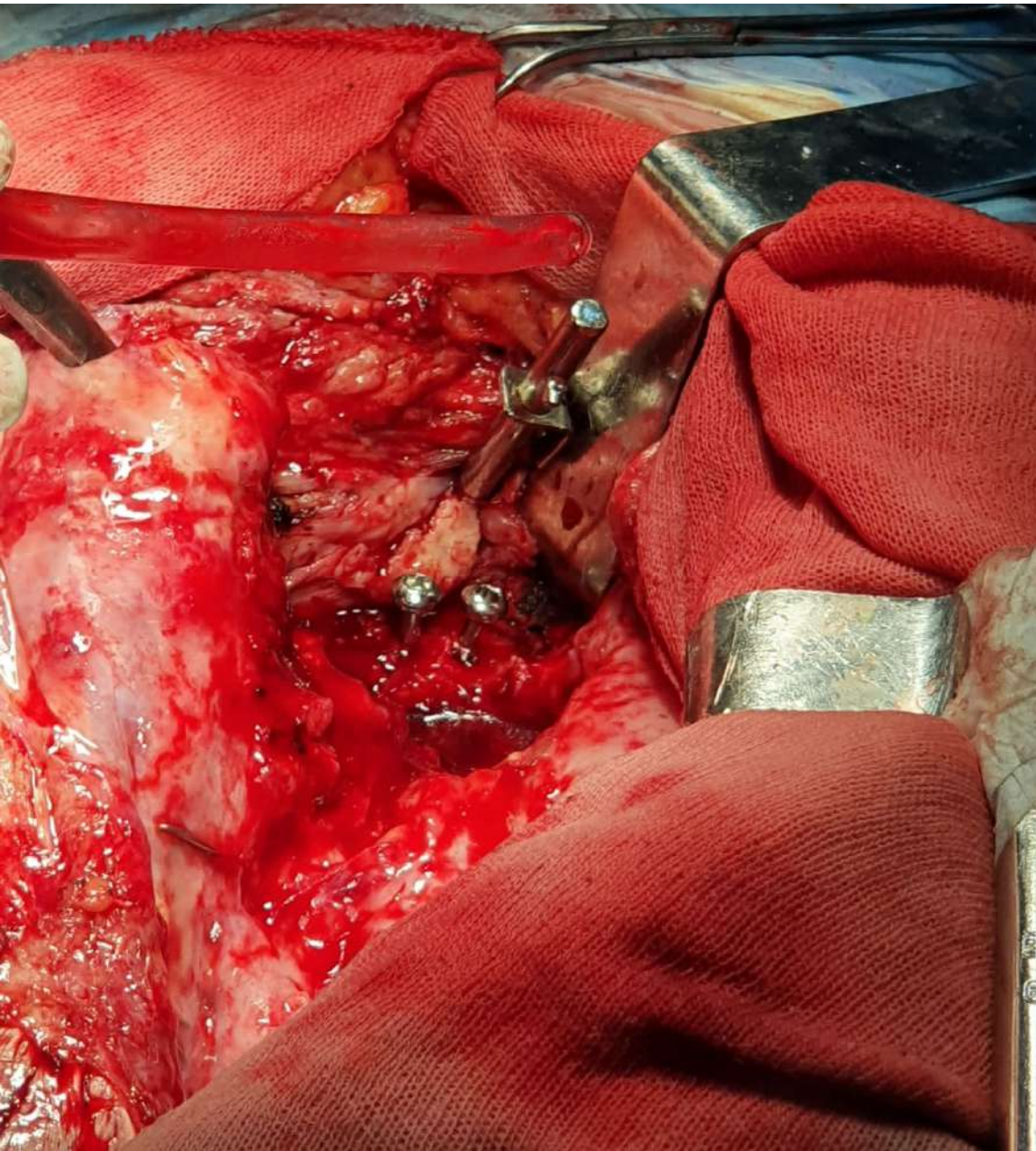


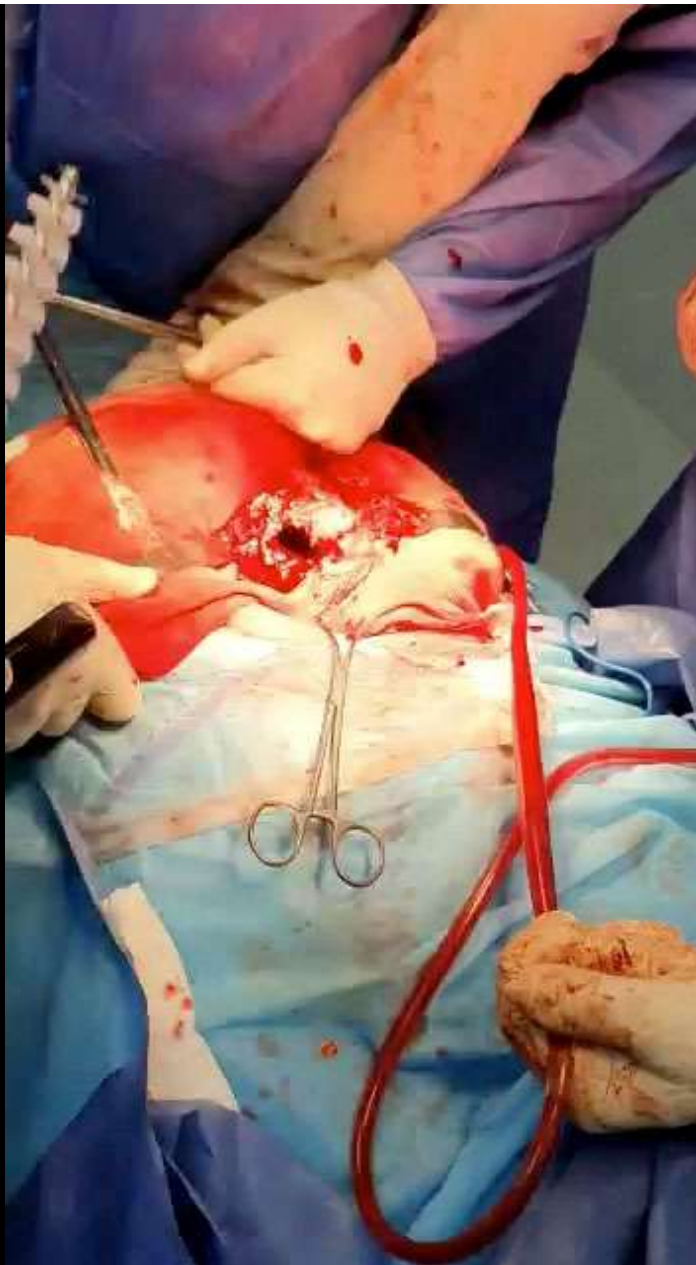




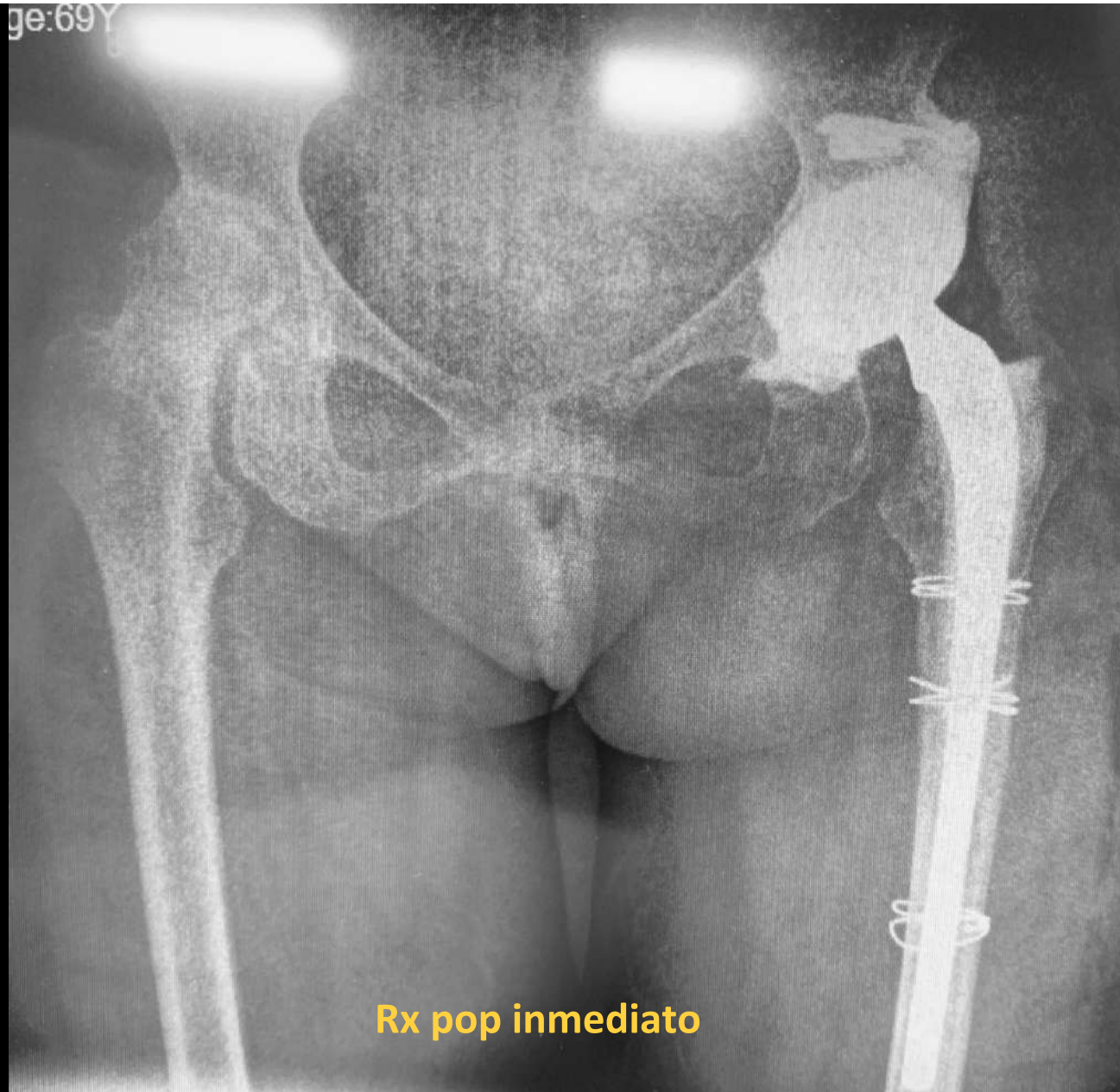






ge:69Y



Rx pop immediato

